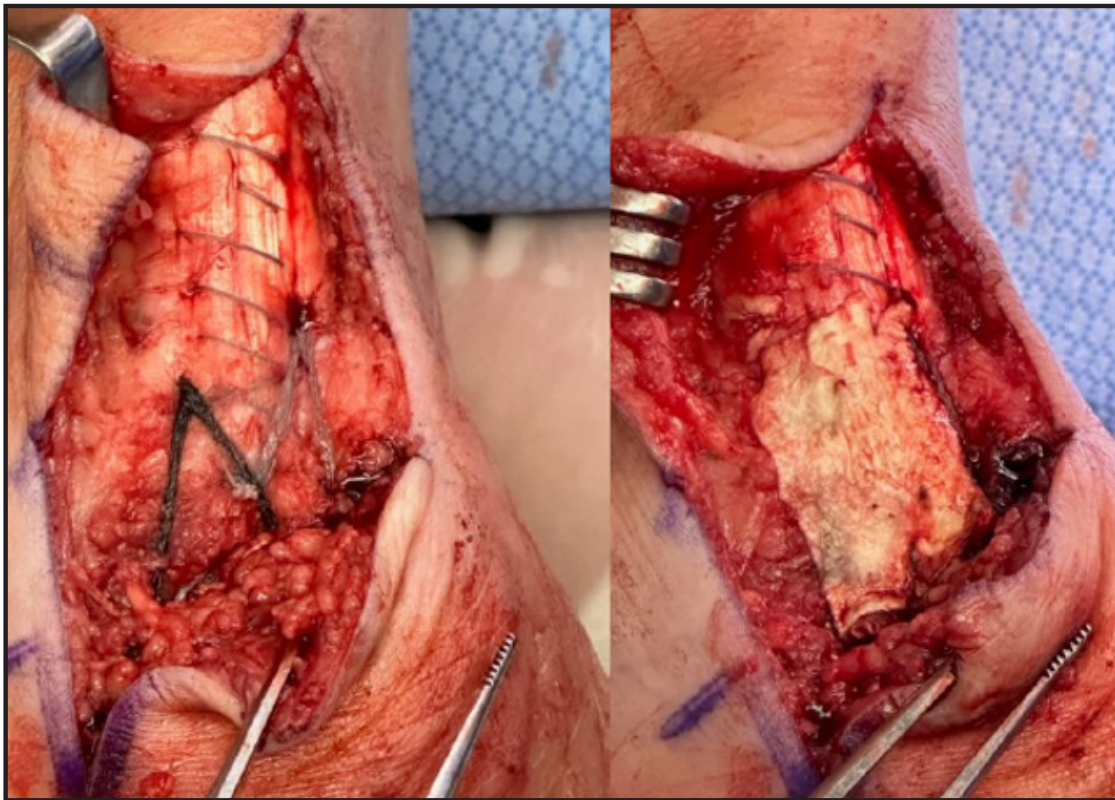


RegeneLink® Amniotic Membrane Allograft

A Case Study

Injury Type: Gastrocnemius equinus, insertional Achilles tendinosis with tendinitis, retrocalcaneal exostosis, tailor's bunion, hypertrophic retrocalcaneal bursa



Repaired Achilles Following
Posterior Calcaneal Exostectomy

Achilles After
Graft Application

Successful use as a protective barrier with a post implant 3 week outcome of reported pain score decrease from 8 to 1 (out of 10).