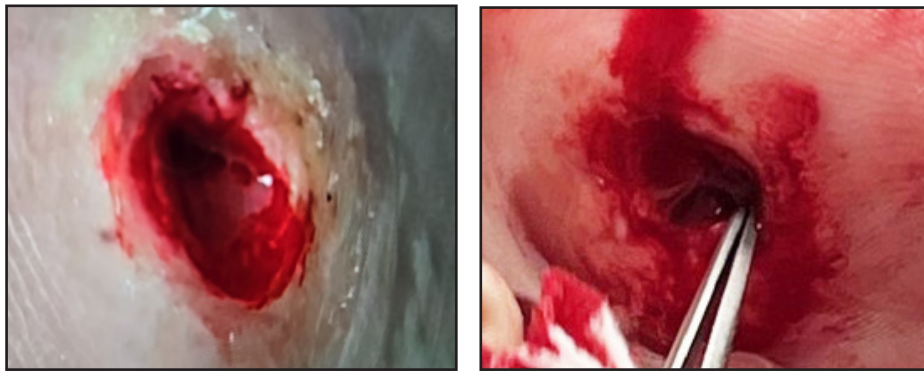


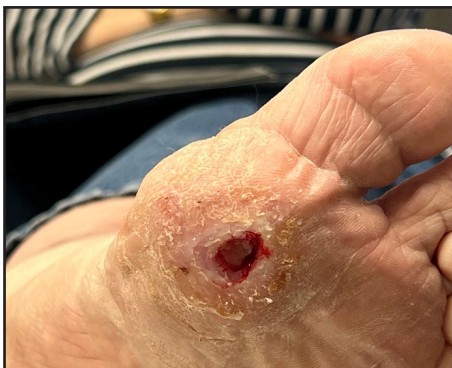RegeneLink® with Liposana® *Amniotic Membrane Allograft with Adipose Allograft* A Case Study

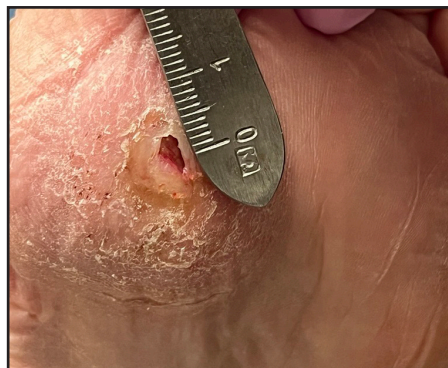Diabetic foot ulcer with a 2+ years history of non-healing
Full wound closure observed post nine applications, after 12 weeks
No reulceration reported since wound closure and Liposana is still palpable



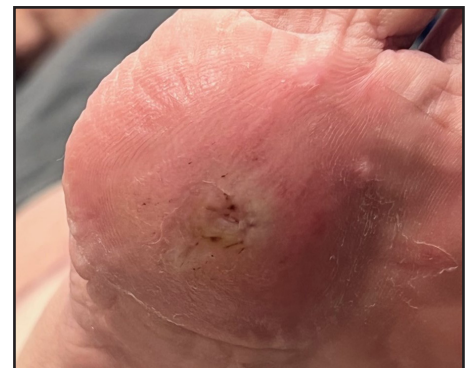Week 0:
Post Wound Debridement
Deep Tunneling Wound



Week 2:
Post 1 Application
(72% Reduction, Deep Tunneling
Wound Significantly Reduced)



Week 5:
Post 4 Applications
(95% Reduction, Deep Tunneling
Wound Has Fully Resolved)



Wound Completely Closed
After 3 Months, and Liposana is
Palpable